

DOI 10.7251/VETJEN1802370V

UDK 616.5-006.6:636.7.09

*Original scientific paper*

## IMPORTANT HISTOLOGICAL AND IMMUNOCHEMICAL PARAMETERS FOR CLASSIFICATION OF CANINE MAST CELL TUMORS<sup>2\*</sup>

**Ivana Vučićević<sup>1\*</sup>, Darko Marinković<sup>1</sup>, Vladimir Kukolj<sup>1</sup>, Slađan Nešić<sup>1</sup>, Milan  
Aničić<sup>1</sup>, Sanja Aleksić-Kovačević<sup>1</sup>**

<sup>1</sup> Department for Pathological Morphology, Faculty of Veterinary Medicine,  
University of Belgrade, Belgrade, Serbia

\* Corresponding Author: Ivana Vučićević, e-mail address: ivucicevic@gmail.com

**Abstract:** Mast cell tumors (MCTs) are one of the most common neoplasms in dogs. They originate from the bone marrow. Several criteria have been proposed for their classification, including histological grading and cell proliferation markers. The mitotic index, multiple nuclei, cells with bizarre nuclei and karyomegaly are the most important parameters for the classification of MCTs on high and low-grade malignancy. For the confirmation of MCT malignancy grade it is also important to determine the expression of the transmembrane kinase (KIT) receptor that has a significant role in the growth and differentiation of mast cell tumors. In high-grade malignancy MCTs in addition to membrane expression of the KIT receptor, aberrant cytoplasmic expression can be also observed. Fifty-two MCTs and 12 control samples of skin from dogs without MCTs were examined. Routinely processed tissue samples were stained with hematoxylin-eosin. Expression of KIT receptor was tested immunohistochemically. The classification of MCTs on high and low-grade malignancy was performed according to the Kiupel's 2-tier classification and the expression of KIT receptors. Sixteen of 52 MCTs were of a low-grade malignancy, while thirty-six were classified as a high-grade malignancy of which 19 MCTs showed aberrant cytoplasm labelling of KIT receptor. All 16 low-grade malignancy MCTs had only membrane expression of KIT receptor. Most high-grade malignancy MCTs showed cytoplasmic KIT expression indicating the link between aberrant KIT expression and increased cell proliferation. The presence of mitotic figures, multinucleated cells, bizarre nuclei and karyomegaly, as well as KIT receptor

<sup>2\*</sup> Presented at the 23rd Annual Consulting of Doctors of Veterinary Medicine of Republic of Srpska (B&H).  
Teslic, June 6-9, 2018

expression pattern are the most important prognostic factors in dogs with mast cell tumor.

**Key words:** *dogs, mast cell tumor, classification, KIT receptor*

## INTRODUCTION

Mast cell tumors are the most common round cell tumors in dogs, and at the same time are the most common skin tumors in this animal species (Welle et al., 2008). Mast cell tumors belong to a group of mesenchymal tumors of the skin and soft tissues (Hendrick et al., 1998). They are composed of differentiated mast cells, which are seen as round cells with different amounts of granules in the cytoplasm, sorted into rows or groups (Strefezzi et al., 2009; Jovanović et al., 2012). Mast cell tumors in dogs are most commonly found on the trunk (50-60%), extremities (25-40%), head and neck (10%). This tumor is less common on scrotum, perineum, back and tail (Welle et al., 2008). The macroscopic appearance of mast cell tumors varies from the degree of differentiation. Well-differentiated mast cell tumors are most commonly present as nodular, nonencapsulated rubber-like mass, above which the areas of the skin are hairless. The size varies from 1 to 4 cm in diameter and they clinically resembles lipoma. Poorly differentiated mast cell tumors have a tendency for faster growth, they are less limited and often accompanied by inflammation and edema of the surrounding tissue (Jubb et al., 2007). Ulceration may occur on their surface, while smaller nodes (satellite nodules) may develop nearby. Most

mast cell tumors are not pigmented, but erythematous and hyperpigmented nodules (Welle et al., 2008) can be observed in occasional findings. The lesions at the distal parts of the limbs, the lips and the groin area may be in the form of poorly defined swellings or resembling acral lick dermatitis (eng.) (Gross et al., 2005; Welle et al., 2008). Malignant mast cell tumors can spread through lymph or blood, and in most cases, the first sign of metastasis is the enlargement of the regional lymph node. Spread to the lungs is not common, while they will most likely spread to the spleen, liver and kidneys. Also they can often be diagnosed on the skin (Morris et al., 2001).

Etiology of mast cell tumors is not fully known, but it is considered, as with most tumors, to be multifactorial. The predisposition of certain breeds shows the importance of genetic in the appearance of MCTs (Welle et al., 2008). Recent papers also emphasize the role of surface receptor tyrosine kinase (KIT protein, CD117) (Vucicevic et al., 2016; Halsey et al., 2017). The diagnosis of mast cell tumors is based on the staining of cytologic smears obtained by fine needle biopsy or by using the impression smears technique. The most commonly used staining methods are Romanowsky

staining (eg Diff-Quik, Giemsa, Wright's) or New methylene blue (London et al., 2003; Strefezzi et al., 2009). While mast cell tumors can be determined on the basis of cytological staining, a histopathological examination of biopsy tissue is indispensable for tumor classification (Bostock, 1973; Patnaik et al., 1984; Kiupel et al., 2011). Mast cell tumors (especially poorly differentiated ones) can be mistaken for other round-cell tumors (lymphoma, plasmacytoma, histiocytoma and transmissible venereal tumour) (Welle et al., 2008; Oliveira et al., 2012). For the purpose of confirming mast cell tumor diagnosis and differentiation from other tumors, toluidine blue (TB) is used for visualizing cytoplasmic granules (London et al., 2003; Strefezzi et al., 2009).

The classification of mast cell tumors is very important when it comes to disease prognosis and type of therapy. The histological examination of mast cell tumors is the primary classification determinant. More recently, a two-stage classification system for mast cell tumors of high and low malignancy has been used. Based on this division, high malignancy mast cell tumors must meet at least one of the following criteria: at least 7 mitotic figures per 10 hpf (High-power Fields – hpf), at least 3 multinucleated cells in 10 hpf, at least 3 bizarre nuclei in 10 hpf or karyomegaly of at least 10% of neoplastic cells (Kiupel et al., 2011). The proposed 2-tier grading system should be used in any routine histological examination and

diagnosis of mast cell tumors. For high grade malignancy MCTs, additional studies such as determination of KIT receptor expression and c-KIT mutation screening should be performed in order to determine adequate therapy (Kiupel et al., 2011, Sabattini et al., 2014).

KIT protein is growth factor receptor of stem cell and is normally found on the surface of hematopoietic cells and mast cells, playing a significant role in the growth and differentiation of these cells. This protein is a type III transmembrane receptor encoded by the proto-oncogene c-kit. KIT receptor expression was detected by immunohistochemical staining both on the surface of normal and on the surface of neoplastic mast cells. Increased expression was observed in poorly differentiated and undifferentiated MCTs (Welle et al., 2008; El-Agamy, 2012). Apart from membrane expression, KIT expression was detected focally and diffusely in the cytoplasm.

The KIT-staining patterns are identified as pattern I - membrane-associated staining due to the localization of KIT proteins in the cell membrane while cytoplasmic staining is present in small amounts or completely absent, pattern II - diffuse cytoplasmic staining and pattern III - also relates to the presence of KIT proteins in the cytoplasm of the neoplastic mast cells and is characterized by intense focal cytoplasmic staining. Expression disorders can contribute to neoplastic transformation (Misdorp, 2004; Takeuchi

et al., 2010). The increased cytoplasmic expression of KIT receptors (focal or diffuse) is correlated with shorter survival of dogs with mast cell tumors and shorter intervals for remission of the disease compared to mast cell tumors

with increased membrane expression (Webster et al., 2004). The aim of our study is to determine the link between the localization of KIT receptors and histologic grade of MCTs observed in dogs.

## MATERIALS AND METHODS

### Animals

The examinations included skin samples of 52 dogs in which MCT is suspected by clinical examination. Samples of unchanged skin of 12 adult dogs, sampled at autopsy, were used as control. Dogs of different breed and sex, ages 3 to 11, were from the territory of the Republic of Serbia. Histopathologic diagnosis was made at the Department of Pathology, Faculty of Veterinary Medicine, University of Belgrade.

### Histopathology

Immediately after the skin tumor biopsy, the samples were fixed in 10% neutral buffered formalin for no more than 48 hours, after which they were processed in the LEICA TP1020 tissue processor. Paraffin blocks were cut using the LEICA RM 2235 microtome into 3-5 µm thick sections. The obtained preparations were stained with hematoxylin-eosin (HE) method. Preliminary pathohistologic diagnosis of MCTs was made on sections stained by hematoxylin-eosin, and for its confirmation, the slides were further stained by toluidin-blue staining kit. Histopathological features of the tumor, such as the presence of mitosis, multinucleated cells, cells with bizarre

nuclei and karyomegaly, were analyzed on slides stained with hematoxylin-eosin. The number of these parameters was determined on ten high power fields of each tumor (400x), using the method described by Romansik et al. (2007). Based on these parameters, the tumors are classified into two levels of differentiation – high grade and low grade tumors.

### Immunohistochemical staining

Formalin-fixed paraffin embedded tissue samples were cut into 5 µm thin sections, which were then stained using a multi-step indirect immunohistochemical (IHC) technique. The sections were incubated with a primary antibody CD117 (Rabbit anti-Human Polyclonal Antibody (DAKO, A4502)) diluted with phosphate buffer saline (PBS) in a ratio of 1:400. Immunoreaction was visualized using DAB + (3,3'-diaminobenzidine tetra-hydrochloride, DAKO, K3468). Mayer's hematoxylin was used for counterstaining. Appropriate positive and negative controls were used.

### Morphometric analysis

For morphometric analysis, Olympus Cell B morphometric software and

Olympus ColorView III camera were used. The localization of KIT proteins was determined in the manner described in Webster et al. research (2007), since membrane KIT proteins and two types of cytoplasmic KIT proteins (focally and diffusely distributed in the cytoplasm) differ. -. Dominant KIT protein pattern was determined based on the presence in at least 10% of neoplastic tumor cells. Cells at the edges of the tumor were not taken into consideration.

### Statistical analysis

Descriptive parameters, such as arithmetic mean and standard deviation, were used in the statistical analysis of the obtained results. Chi-square test was used to test and determine statistically significant differences. These tests determined the existence of a statistically significant difference between the tested parameters at the significance level of 5% and 1%.

## RESULTS

Histological analysis of tissue sections stained with hematoxylin and eosin revealed more than six mitotic figures per 10 hpf in 53.85% of MCTs (Figure 1a), while 46.15% of MCTs were characterized by poor mitotic activity. The presence of more than two multinucleated cells in 10 hpf was observed in 59.61% of MCTs (Figure 1b). In 17.31% of MCTs, two multinucleated cells were present, while one multinucleated cell was observed in 19.23% of MCTs on the same number of visual fields. Multinucleated cells were not observed in 3.85% of MCTs. More than two cells with bizarre nuclei in 10 hpf were present in 55.77% of MCTs (Figure 1c). Two cells with bizarre nuclei on the same number of visual fields were observed in 7.69% MCTs, while one cell with bizarre nuclei was present in 26.92% of MCTs. In 9.61% of MCTs, cells with bizarre nuclei were not detected. More than 10% of anaplastic mast cells with nuclei of about 8-10 micrometers in diameter were observed in 19.23% of MCTs, while 42.30% of MCTs contained

less than 10% of the cells with increased nucleus (Figure 1d). In 38.46% of MCTs no karyomegaly was present.

Based on the criteria of Kiupel's classification and established parameters (mitotic figures, multinucleated cells, bizarre nuclei and karyomegaly,) in diagnosed MCTs, 36 (69.23%) of MCTs corresponded to MCTs of higher malignancy, while 16 (30.77 %) of MCTs were of a lower degree of malignancy. Immunohistochemical staining confirmed the presence of KIT receptors in skin tissue sections of the dogs with MCTs. Microscopic examination of the sections revealed three types of immunohistochemical staining patterns for KIT positive cells. The majority of MCTs in this study had KIT expression pattern I or membrane expression (63.46%) (Figure 1e). This group included all low grade malignancy MCTs and 17 out of 36 high grade malignancy MCTs. Expression pattern II was present in 21.15% mast cell tumors

(Figure 1f), all of which were high grade. None of the examined mast cell tumors had only pattern III, but combined patterns were observed, namely: 11.54%

of MCTs exhibited membrane and focal cytoplasmic expression, while 3.85% of MCTs had membrane and diffuse cytoplasmic expression of KIT receptors.

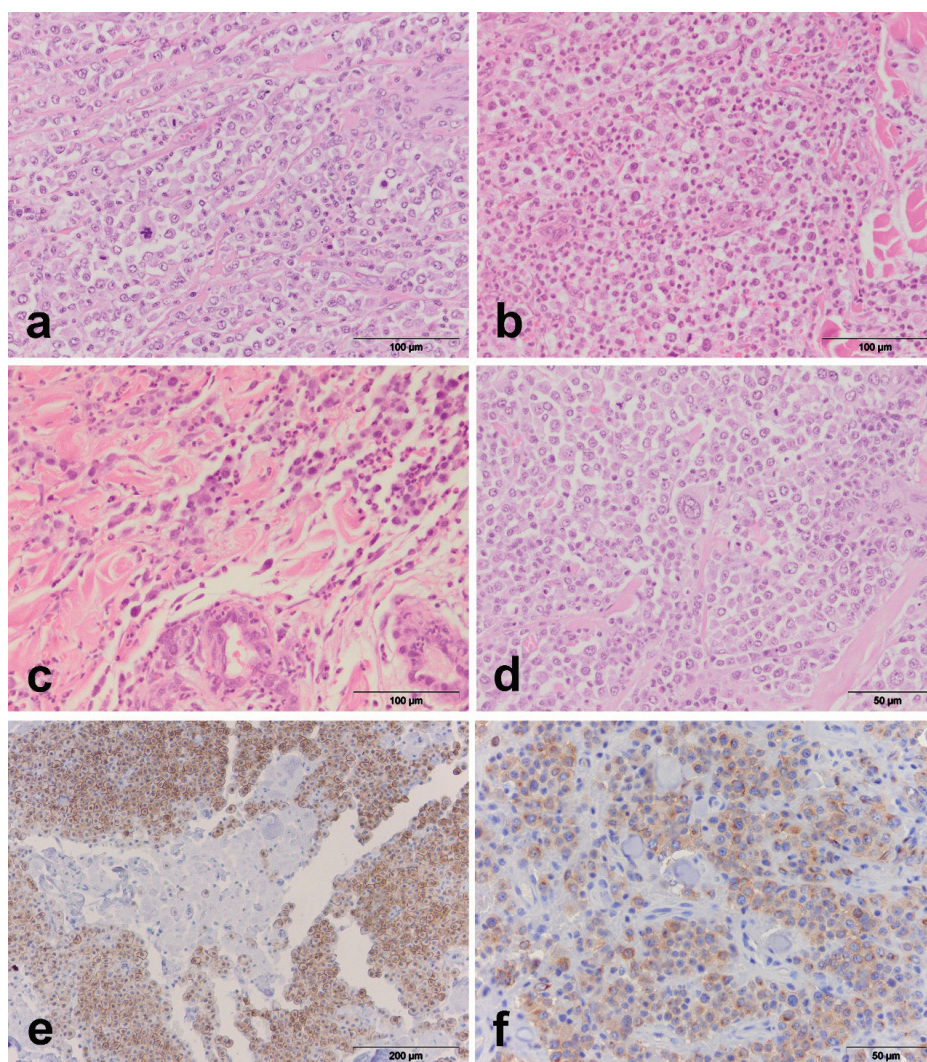


Figure 1. Skin, dog: a) The presence of mitotic figure in high grade MCT, HE; b) The presence of multinucleated cells in high grade MCTs, HE; c) The presence of cells with bizarre nuclei in high grade MCTs, HE; d) The presence of karyomegaly in high grade MCTs, HE; e) Expression of pattern I (membrane expression), CD117, LSAB2; f) Expression of pattern II (diffuse cytoplasmic expression), CD117, LSAB2;

## DISCUSSION

Mast cell tumors are the most common dog skin tumors, especially when it comes to certain breeds such as boxer, golden retriever, labrador retriever and others (Welle et al., 2008). Based on the results obtained in our study, the highest incidence of mast cell tumors was observed in golden retrievers (37.5%), followed by boxers (20.7%). Similar to these results, most authors state that mast cell tumors were most commonly diagnosed in boxers (London and Sarah, 2003; Webster et al., 2006a; Gil da Costa et al., 2007; Welle et al., 2008; Vucicic et al., 2018). Others consider that although boxers have an increased risk of mast cell tumor formation, they are usually of low grade malignancy and have a more favorable prognosis (Thamm et al., 2007).

Histological examination appears to be the most consistent predictive parameter and is closely related to the 2-tire classification system proposed by Kiupel (Kiupel et al., 2011) according to which mast cell tumors are divided into high grade and low grade MCTs. According to the 2-tire system, MCTs examined in our research have been classified in high grade and low grade MCTs. Out of 52 MCTs in dogs, thirty-six were high grade tumors, while sixteen MCTs had morphological characteristics indicating a low degree of malignancy. More than six mitotic figures per 10 hpf were detected in 77.78% of high grade MCTs, and the presence of mitotic figures is statistically significant parameter

for classification of MCTs in this study. While some authors consider that low grade MCTs can metastasize, and that determining only the mitotic index is not a reliable way of predicting tumor behavior (Séguin et al., 2006; Webster et al., 2007); other authors consider mitotic activity to be an important feature for the prognosis of mast cell tumor behavior (Romansik et al., 2007; Kiupel et al., 2011). Some authors believe that mortality increases in cases where the mitotic index is greater than 5/10 hpf (O'Connell and Thomson, 2011).

The presence of more than two multinucleated cells in 10 hpf was observed in 86.11% of high-grade MCTs, indicating that this is a statistically significant indicator of MCTs classification. Some studies indicate that there is a significant correlation between the number of multinucleated cells in MCTs and survival time, so that survival time decreases with the increase in the number of multinucleated cells (Thompson, 2012).

In our study, the presence of more than two cells with bizarre nuclei in 10 hpf was observed in 86.11% of high grade MCTs, while the presence of multinucleated cells in low grade MCTs was not observed.

It was also observed that 27.78% of high grade MCTs contain more than 10% anaplastic MCTs with nuclei of 8-10 microns in diameter, indicating that the karyomegaly can not be considered

as a significant predictive factor in this study. There is a significant correlation between high grade MCTs and faster metastases, as well as a shorter survival time of patients (Kiupel et al., 2011; Stern, 2012). Therefore, for high grade mast cell tumors, additional tests such as determining the expression of KIT receptors and screening for mutations of c-KIT should be used in order to determine adequate therapy.

Recent studies indicate the existence of both normal (membrane) and aberrant cytoplasmic (focal and diffuse) KIT receptor expression of MCTs in dogs (Morini et al., 2004; Gil da Costa et al., 2007). Unlike previous studies (Reguera et al., 2000) which examined the relationship between intensity of immunohistochemical staining indicating the degree of KIT expression and the degree of tumor malignancy, our study examines the interconnection of aberrant expression of this protein and histopathological grade of mast cell tumor. In our study, it is observed that in low grade MCTs there is only membrane expression, while in high grade MCTs, in addition to membrane expression, there is also aberrant expression. From our results, it is noted that low grade MCTs have no aberrant expression of the KIT receptor. None of aberrant expression pattern is statistically significant in relation to other aberrant expression patterns.

However, the correlation between aberrant CD117 expression and the

degree of tumor malignancy is clear. Some authors state that KIT receptor is a transmembrane protein, and as such, the immunoreactivity of this protein is localized on the cytoplasmic membrane of unchanged mast cells. The results of the study confirm that canine MCTs that have more aggressive biological behavior, they also have greater cytoplasmic KIT expression (Kiupel et al., 2004). Also, the same authors claim that mast cells with increased cytoplasmic KIT expression have an increased risk of local recurrence and shorter survival time. Some authors emphasize a strong correlation between the cytoplasmic (aberrant) immunoexpression and increased cell proliferation, and therefore a higher degree of malignancy, but they did not notice significant differences between the focal and diffuse cytoplasmic CD117 expression, suggesting that focal and diffuse cytoplasmic expression of KIT receptor may reflect similar cell changes. It is known that cytoplasmic KIT receptor expression is associated with both necrotic and ulcerative changes. Cytoplasmic KIT receptor expression is related to increased mast cell proliferation, and the occurrence of necrosis in mast cell tumors can be a reflection of increased cell proliferation which appropriate angiogenesis isn't able to follow. On the other hand, the correlation between the cytoplasmic KIT receptor expression and occurrence of epidermal ulcerations can be due to KIT-mediated release of histamine and serotonin, which causes intense itching (Gil da Costa et al., 2007).

## CONCLUSION

More recently, the presence of c-kit proto-oncogene mutation and aberrant KIT expression are considered to be the most prominent predictive factors. However, some papers state that aberrant KIT receptor expression can be seen in high grade MCTs in which no mutation was detected (Webster et al., 2006, Vucicevic et al., 2016). Therefore, determination of KIT receptor expression should be part of routine diagnostics and classification of mast cell tumors in dogs.

## LITERATURE

1. Bostock D.E., Crocker J., Harris K., Smith P (1989): Nucleolar organiser regions as indicators of post-surgical prognosis in canine spontaneous mast cell tumours. *British Journal of Cancer* 59(6): 915–18.
2. El-Agamy D.S (2012): Targeting c-KIT in the therapy of mast cell disorders: current update. *European Journal of Pharmacology* 690(1-3): 1-3.
3. Gil da Costa R.M., Matos E., Rema A., Lopes C., Pires M.A., Gartner F (2007): CD117 immunoexpression in canine mast cell tumours: correlations with pathological variables and proliferation markers. *BMC Veterinary Research* 21(3): 19.
4. Gross T.L., Ihrke P., Walder E.J., Affolter V.K (2005): Mast cell tumors. *Skin Diseases of the Dog and Cat Clinical and Histopathologic Diagnosis*. 2nd edn. Oxford, UK: Blackwell Science Ltd 853–65.
5. Halsey C.H.C., Thamm D.H., Weishaar K.M., Burton J.H., Charles J.B., Gustafson D.L., Avery A.C., Ehrhart E.J (2017): Expression of Phosphorylated KIT in Canine Mast Cell Tumor. *Veterinary Pathology* 54(3): 387-394.
6. Hendrick M.J., Mahaffey E.A., Moore F.M., Vos J.H., Walder E.J (1998): Mast cell tumors. In: *World Health Organization International Histological Classification of Tumors of Domestic Animals, Histological Classification of Mesenchymal Tumors of the Skin and Soft Tissues of Domestic Animals*. 2nd series, ed. Schulman FY, 28–29. Armed Forces Institute of Pathology, Washington, DC.
7. Jovanović M., Aleksić-Kovačević S., Knežević M (2012): *Specijalna veterinarska patologija*, Makarije d.o.o., Beograd.
8. Jubb, Kennedy, Palmer (2007): *Pathology of Domestic Animals*, Saunders Elsevier, 5th edition, 771-73.
9. Kiupel M., Webster J.D., Kaneene J.B., Miller R., Yuzbasiyan-Gurkan V (2004): The use of kit and tryptase expression patterns as prognostic tools for canine

- cutaneous mast cell tumors *Vet Pathol* 41(4): 371-77.
10. Kiupel M., Webster J.D., Bailey K.L., Best S., DeLay J., Detrisac C.J. i sar. (2011): Proposal of a 2-Tier Histologic Grading System for Canine Cutaneous Mast Cell Tumors to More Accurately Predict Biological Behavior. *Veterinary Pathology* 48(1): 147-55.
  11. London C.A., Seguin B (2003): Mast cell tumors in the dog. *Veterinary Clinics of North America Small Animal Practice* 33(3): 473-89.
  12. Misdorp W (2004): Mast cells and canine mast cell tumours: a review. *Veterinary Quarterly* 26(4): 156-69.
  13. Morris J., Dobson J (2001): *Small Animal Oncology*. Blackwell Science 59-62.
  14. O'Connell K., Thomson M (2011): Evaluation of prognostic indicators in dogs with multiple, simultaneously occurring cutaneous mast cell tumours: 63 cases. *Veterinary and Comparative Oncology* 11(1): 51-62.
  15. Oliveira F.N., Elliott J.W., Lewis B.C., Mathews G.G., Brown R.M., Treadway C.M., Langohr I.M (2013): Cutaneous Mast Cell Tumor With Epitheliotropism in 3 Dogs. *Veterinary Pathology* 50(2): 234-37.
  16. Patnaik A.K., Ehler W.J., MacEwen E.G (1984): Canine cutaneous mast cell tumor: morphologic grading and survival time in 83 dogs. *Veterinary Pathology* 21(5): 469-74.
  17. Reguera M.J., Rabanal R.M., Puigdemont A., Ferrer L (2000): Canine mast cell tumors express stem cell factor receptor. *Am J Dermatopathol* 22(1): 49-54.
  18. Romansik E.M., Reilly C.M., Kass P.H., Moore P.F., London C.A (2007): Mitotic index is predictive for survival for canine cutaneous mast cell tumors. *Vet Pathol* 44(3): 335-41.
  19. Sabattini S., Scarpa F., Berlato D., Bettini G (2014): Histologic grading of canine mast cell tumor: Is 2 better than 3?. *Vet. Pathol* 52(1): 70-3
  20. Seguin B., Besancon M.F., McCallan J.L. I sar. (2006): Recurrence rate, clinical outcome, and cellular proliferation indices as prognostic indicators after incomplete surgical excision of cutaneous grade II mast cell tumors: 28 dogs (1994-2002). *J Vet Intern Med* 20: 933-940.
  21. Stern W.A (2012): Histologic Grading of Canine Cutaneous Mast Cell Tumors: Is There a Good System?. *J Vet Sci Med Diagn* 1: 1.
  22. Strefezzi R.F., Kleeb S.R., Xavier J.G., Catao-Dias J.L (2009): Prognostic indicators for mast cell tumors. *Bray J Vet Pathol* 2: 110-21.

23. Takeuchi Y., Fujino Y., Watanabe M., Nakagawa T., Ohno K., Sasaki N., Sugano S., Tsujimoto H (2010): Aberrant autophosphorylation of c-KIT receptor in canine mast cell tumor cell lines. *Vet. Immunol. Immunopathol* 137(3-4): 208-16.
24. Thamm D.H., Vail D.M: Mast cell tumors, In: Withrow SJ, MacEwen EG, editors (2007): *Small Animal Clinical Oncology*, Saunders, Philadelphia.
25. Thompson J.J (2012): *Canine Mast Cell Tumours: Characterization of Subcutaneous Tumours and Receptor Tyrosine Kinase Profiling*. PhD Thesis, Guelph, Ontario, Canada.
26. Vučičević, I., Marinković, D., Kukolj, V., Nešić, S., Aničić, M., Aleksić-Kovačević, S (2016): Kit receptor expression in canine cutaneous mast cell tumours (CMCTS) without c-kit mutation. *Acta Veterinaria-Beograd* 66 (2): 222-233
27. Vučičević I., Marinković D., Kukolj V., Nešić S., Aničić M., Aleksić-Kovačević S (2018): Mast cell tumor within a lipoma in a white toy poodle. *Veterinarski Glasnik*, 72 (1): 64-67.
28. Webster J.D., Kiupel M., Kaneene J.B., Miller R., Yuzbasiyan-Gurkan V (2004): The use of KIT and tryptase expression patterns as prognostic tools for canine cutaneous mast cell tumors. *Vet Pathol* 41(4): 371-7.
29. Webster J.D., Yuzbasiyan-Gurkan V., Kaneene J.B., Miller R., Resau J.H., Kiupel M., (2006): The role of c-KIT in tumorigenesis: evaluation in canine cutaneous mast cell tumors. *Neoplasia* 8(2): 104-11.
30. Webster J.D., Yuzbasiyan-Gurkan V., Miller R.A., Kaneene J.B., Kiupel M (2007): Cellular proliferation in canine cutaneous mast cell tumors: associations with c-KIT and its role in prognostication. *Veterinary Pathology* 44(3): 298-308.
31. Welle M.M., Rohrer C.B., Howard J., Rüfenacht S (2008): Canine mast cell tumours: a review of the pathogenesis, clinical features, pathology and treatment. *Veterinary Dermatology* 19(6): 321-39.

Paper received: 30.04.2018.

Paper accepted: 11.10.2018.